

Chiari-like Malformation and Syringomyelia (CM/SM)

Clare Rusbridge BVMS PhD DECVN MRCVS, European and RCVS Specialist in Neurology

neuro.vet@btinternet.com Stone Lion Veterinary Centre, 41 High St, Wimbledon, SW19 5AU. Fax 020 8944 0871

Syringomyelia: a condition whereby fluid filled cavities (syrinxes*) develop within the spinal cord

Cause any blockage to the cerebrospinal fluid (CSF) flow.

- Chiari-like malformation – a mismatch between brain and skull volume where the brain is too big and the skull too small. The outflow of CSF at the back of the skull is blocked.
- any other space occupying lesion blocking CSF flow e.g. tumors

Diagnosis- currently can only be confirmed by MRI

Clinical signs usually recognized between 6 months and 6 years of age. However, SM is a 'late onset' condition and dogs of any age may be presented. Dogs with more severe disease tend to have their first signs before 4 years of age.

- **PAIN** - may be difficult to define or intermittent
 - worse at night
 - when first getting up
 - during hot or cold temperature extremes
 - when excited
 - related to posture e.g. preferring to sleep with head raised.
 - may have sensitive area neck / ear / shoulder / sternum.
- Often **SCRATCH** at shoulder, ear, neck or sternum
 - typically one side only
 - while moving sometimes without making skin contact
- **SCOLIOSIS** - twisted neck or tilted head
- **FORE AND HINDLIMB WEAKNESS**
- **ATAXIA (wobbliness).**
- Facial nerve paralysis, balance problems, deafness and seizures may be associated with the condition but a definite

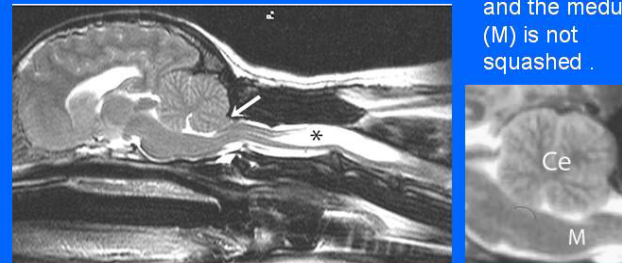
Syringomyelia DNA Research is focused on the treatment, pathogenesis and genetics of the condition. The inheritance is complex probably involving the interaction of gene/s and other factors. A full genome scan has been initiated with our collaborators in Canada, following an international collection of DNA. The search for the gene/s is led by Guy Rouleau MD PhD FRCP(C) Director of the Center for the Study of Brain Diseases Montreal. The research is focused on identifying genetic markers/genes which then can be used as genomic breeding value for the individual (GBV). These are accurate and exist at birth, so an MRI would not be necessary for diagnosis. This research is done in collaboration with Dr Sarah Blott at the Animal Health Trust, the Roslin Institute, Cambridge University and the UK Kennel Club, and an ultimate aim is to provide the breeder with an 'on-line' breeding programme using computer 'tools' to select mate/s for their dogs. This would not only give desired physical characteristics but take account of the inherited traits in the breed.

Meanwhile, in an attempt to reduce the incidence of the disease, breeding recommendations have been suggested.

Chiari malformation -the space holding the hindbrain is too small

In this MRI of a CKCS, part of the cerebellum is sticking out of the skull (arrowed) obstructing the flow of cerebrospinal fluid. As a result, a large syrinx (*) has developed in the spinal cord, filled with fluid which appears white in the scan.

This skull has more room for brain so that the cerebellum (C) looks rounded and the medulla (M) is not squashed.



Treatment - medical

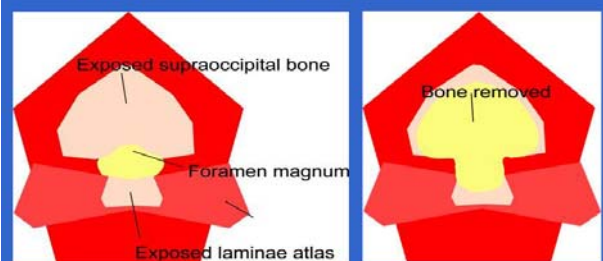
Long-term studies of medical management of syringomyelia are not available yet. The drugs used to treat syringomyelia can be divided into 3 types:

- analgesics
- drugs which reduce CSF production
- corticosteroids

Surgical management

- Surgical management is indicated for dogs with a poor response to medical management
- The aim is to restore CSF dynamics and if this can be achieved then the syrinx can resolve.
- The most common procedure is **suboccipital decompression** to enlarge the space at the back of the brain

Suboccipital decompression surgery



More information <http://sm.cavalierstalk.com>

Or contact

Thanks to all the dedicated vets, breeders and pet owners who have contributed time, effort and money to help the breed

UK----Europe (especially Netherlands) ----USA----Canada-----Australia

© Clare Rusbridge BVMS DipECVN MRCVS